

Non-Responding Knee Pain with Osteoarthritis, Meniscus and Ligament Tears Treated with Ultrasound Guided Autologous, Micro-Fragmented and Minimally Manipulated Adipose Tissue

Richard David Striano¹, Valeria Battista^{2*}, Norma Bilboo¹

¹Optimum Joint, New York, USA

²Istituto Image, Milano, Italy

Email: *ieia.battista@gmail.com

How to cite this paper: Striano, R.D., Battista, V. and Bilboo, N. (2017) Non-Responding Knee Pain with Osteoarthritis, Meniscus and Ligament Tears Treated with Ultrasound Guided Autologous, Micro-Fragmented and Minimally Manipulated Adipose Tissue. *Open Journal of Regenerative Medicine*, 6, 17-26.

<https://doi.org/10.4236/ojrm.2017.62002>

Received: May 14, 2017

Accepted: June 24, 2017

Published: June 27, 2017

Copyright © 2017 by authors and Scientific Research Publishing Inc. This work is licensed under the Creative Commons Attribution International License (CC BY 4.0).

<http://creativecommons.org/licenses/by/4.0/>



Open Access

Abstract

Background: Chronic knee pain from advanced osteoarthritis is often associated with tears in the fibro-cartilaginous meniscus and cruciate ligaments. The result is substantial pain and impairments and loss of daily function, thus limiting activity and quality of life. These often include pain, loss of range of motion, inability to elevate the leg, pain increased with activity and gradual worsening over time. This represents a challenging clinical picture for which few non-surgical options are available. Most patients failing to respond to current methods of care are offered arthroplasty. Current therapies are focused on the relief of the symptoms but cannot repair the damage nor stop the degenerative process. **Objective:** This is a case study of the first subject in a continuing IRB to reach a 2.5 year end-point. Our intention was to investigate the potential benefits of using autologous, minimally manipulated fat graft in subjects with advanced osteoarthritis and meniscus pathology who had failed to obtain benefit from previous, standards of care. Study description: 73 YO male, end stage bone-on-bone right knee pain. First subject to reach the 2 1/2 year follow up after Lipogems® precision ultrasound guided injections. **Material and Methods:** Micro-fragmented fat was obtained using a minimal manipulation technology in a closed system, Lipogems®, without the addition of enzymes or other additives. Fat graft was injected under continuous ultrasound guidance. **Results:** VAS pain, KOOS function, range of motion and quadriceps strength improved after treatment. **Conclusion:** Autologous, micro-fragmented, and minimally manipulated adipose tissue resulted in significant improvement in pain, function and quality of life. No adverse events were reported.

Keywords

Stem Cells, Adipose Graft, Knee Arthritis, Lipogems®, Knee Pain, Micro-Fragmented Adipose Tissue, MSC Properties, Osteoarthritis

1. Introduction

Advanced osteoarthritis (OA) of the knee is common and about 13% of women and 10% of men aged 60 years and older have symptomatic knee OA. Population affected with symptomatic Knee OA is increasing because of aging of the population and increasing of obesity or overweight in general population [1].

Chronic knee pain from advanced osteoarthritis is often associated with tears in the fibro-cartilaginous meniscus and cruciate ligaments. The result is substantial pain, impairments and loss of daily function, thus limiting activity and quality of life, often include loss of range of motion, inability to elevate the leg, pain increased with activity and gradual worsening over time.

Current therapies, both surgical (arthroplasty) and not surgical (physical therapy, injection of hyaluronic acid, steroids injection), are focused on the relief of the symptoms but cannot repair the damage nor stop the degenerative process at the adjacent levels [2] [3] [4] [5] [6].

In the past few years regenerative medicine focused on new strategies to slow down the degeneration process in joints and obtain tissues regeneration [7] [8].

In vitro and in vivo experimental studies have demonstrated that human mesenchymal stem cells (MSCs) differentiate in vitro into many cell lineages, such as osteoblasts, chondrocytes, myocytes, and adipocytes [9].

In the past 15 years, it has been shown that human MSCs also can promote vasculogenesis, which is the main mechanism involved in tissue repair. In addition, MSCs secrete a variety of bioactive molecules that act in a paracrine fashion to prime and sustain angiogenic, antifibrotic, antiapoptotic, and immunomodulatory responses in target tissue [9] [10].

The concept that fat tissue is an optimal source for MSCs which is now established, supported by their abundance and compared to other tissues [11] [12] [13]. Indeed, 1/100 cells in the adipose tissue are MSCs compared to 1/100,000 cells in the bone marrow.

Fat tissue is easily available in most patients; it can be harvested with a minimally invasive approach, offering a highly viable MSC population with optimal differentiation potential which is maintained with aging [14].

In the last few years, in literature appeared some studies about the improvement of the therapeutic effects provided by the traditional fat transfer and fat grafting techniques [15] [16].

To increase the regenerative potential MSC enrichment techniques based on enzymatic [17] [18] or mechanical [19] [20] devices have been proposed.

The less manipulated fat tissue seems to work clinically better than enzymati-

cally isolated stem cells (both as svf or cultivated). In less manipulated fat tissue are preserved both cells and the niche: a natural adipose scaffold which is the “perfect functional unit” [11].

Mechanically derived MSC versus enzymatically isolated MSC have shown to have better differentiation potential, much larger secretome content, and a large difference in exosomes contents [14] [21] [22].

For this reason, a new device, named Lipogems®, has been developed [12] [13] [14]. The technique is non-traumatic and intra-operatively provides micro-fragmented adipose tissue in a short time (15 - 20 minutes). The fat tissue is treated mechanically without expansion and/or enzymatic treatment. Lipogems® device provides autologous, micro-fragmented, and minimally manipulated adipose tissue graft [11] [21].

Intraarticular ultrasound guided injection of autologous micro fragmented fat tissue provide excellent results in terms of pain, function, improvement of quality of life and may potentially stop the degenerative process by repair and regeneration of injured or damaged soft tissues.

In this case report we present a case of chronic worsening knee pain that failed prior standards of care including arthroscopic surgery, from advanced osteoarthritis and meniscal tears treated with the autologous adipose tissue using the Lipogems technology with a follow up of 2.5 years.

2. Case Presentation

The subject is a 73 YO male. The patient has advanced tricompartmental osteoarthritis and failed prior treatment including cortisone injection, non-ablative cryotherapy to the genicular nerves, hyaluronic acid injections, platelet rich plasma injection and arthroscopic meniscectomy of the medial and lateral meniscus. Patient was scheduled for joint replacement as it was his only option but he refused surgery.

His right knee pain was constant, significantly affecting quality of life. Examples include that he could barely bend the knee, walking “straight-legged” and could not do simple activity such as putting on socks because he couldn’t bend the knee far enough. He had to wear slip on shoes and couldn’t put on pants without the help of his wife because of restricted range of motion. He went up steps one step at a time. He used to ride a bike and could no longer do that. His quality of life was extremely impaired with knee OA.

The preoperative MRI revealed degenerative tear of the ACL, degenerative PCL, medial meniscus anterior and posterior horn portions not visualized, portion of the anterior horn lateral meniscus not visualized, bone marrow edema and sub centimeter cyst medial femoral condyle. In addition there is advanced bone-on-bone medial and lateral joint osteoarthritis and chondromalacia patella.

3. Materials and Methods

The procedure was performed under local anesthesia. The donor site was the abdomen on each side below and laterals to the umbilicus. Before harvesting the

fat tissue, the entry point for harvest was injected with local anesthesia. Two small incisions were performed with the bevel of an 18 G needle, and 250 cc of anesthetic tumescent fluid was injected using a 17 G blunt cannula channeling on a spokes on a wheel fashion. The fat (60 cc) was then harvested using a 13 G blunt cannula attached to a Vaclok 30 ml syringe and introduced into the Lipogems® processing kit.

A complete diagnostic musculoskeletal ultrasound examination was performed to gain real-time information and map/visualize each point of interest for deployment of the treatment. 1 cc aliquots of fat graft were injected under continuous ultrasound guidance. 3 cc's were injected into the medial compartment in an infrapatellar approach. 3 cc's were injected into the lateral compartment in an infrapatellar approach. 1 cc was injected into each the medial and lateral meniscus. 2 cc's were injected into anterior cruciate ligament.

Ultrasound guidance was administered using a GE logiqP6 ultrasound unit with a ML5-15 MHz matrix linear probe.

No peri-procedural complications or adverse events were observed.

4. Outcome Measures

Pre and post treatment clinical outcomes were determined using the NPS pain scale with no separate walking function scores, recording functional impairment with Knee Injury and Osteoarthritis Outcome Score (KOOS), measuring the range of motion by instrumentation and assessing quadricep strength measured digitally. Follow up is at designated time points to 2 ½ years after the procedure.

5. Ethics

The procedure mentioned in this case report is in accordance with the ethical standards and with the Helsinki Declaration of 1975, as revised in 2000. The patient has been informed about risks, benefits and alternative options to the proposed treatment and expressed and signed the informed consent form.

6. Results

In the immediate post injection period, there was a significant decrease in pain, as noticed in previous studies and other patients treated with this technique.

KOOS function score was 25/100 with 100 being perfect score. Range of motion was 0 - 50 degrees with fully extension and flexion impairment, with 135 degrees being normal. Strength measured digitally in lbs./in² was 7.

After a 2 ½ years follow up NPS pain is 1/10. KOOS function is 71/100. Range of motion is 0 - 105 degrees. Quadriceps strength is 27 lbs/in². First post treatment clinical evaluation was taken at month 6 (**Figures 1-8**).

7. Discussion

Considering the increasing of general population age and obesity and the resulting increasing of joints OA is mandatory to provide curative option for

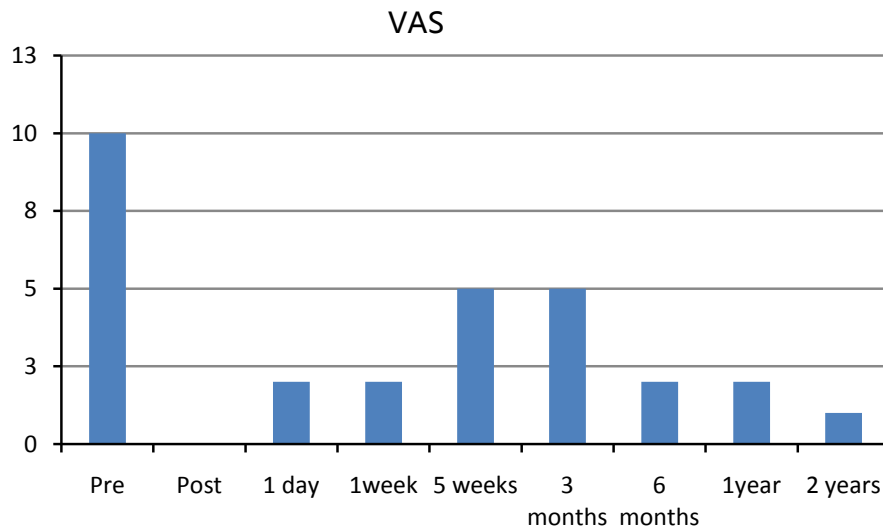


Figure 1. VAS scale 0 - 10 with 10 being worst pain.

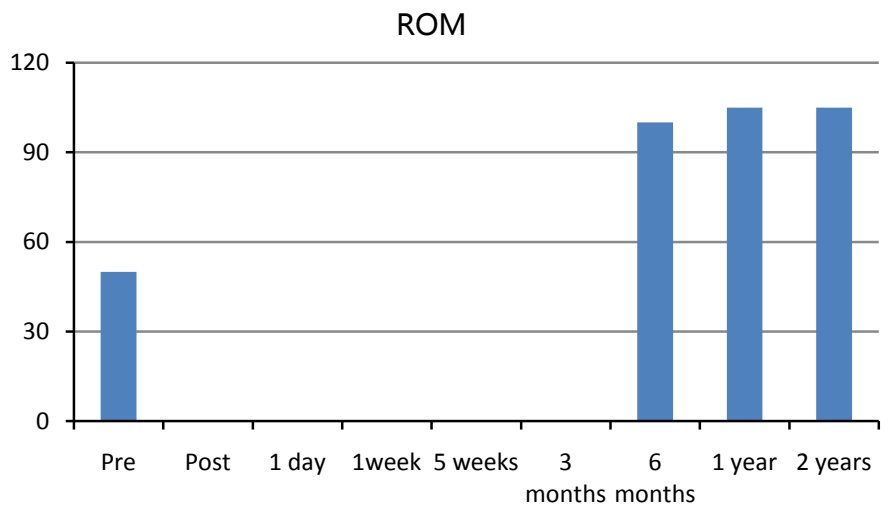


Figure 2. Range of motion 0 - 153 degrees.

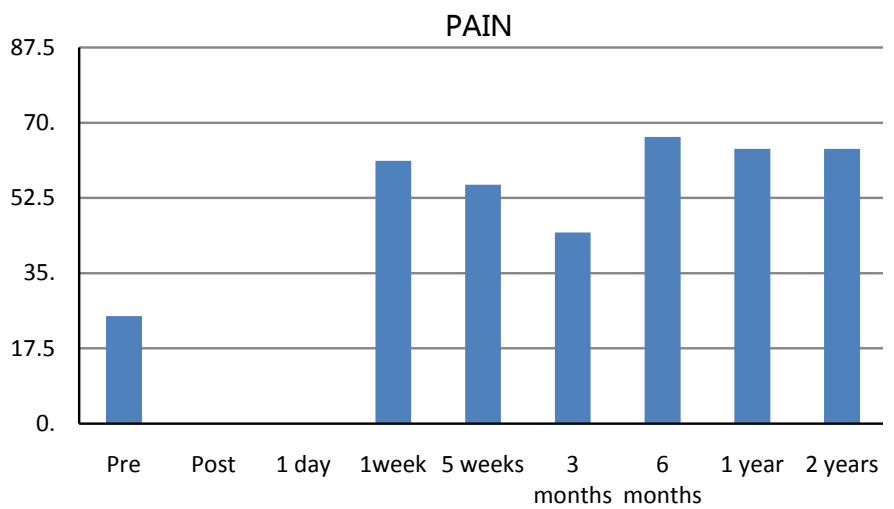


Figure 3. KOOS pain score 0 - 100. 100 is no pain.

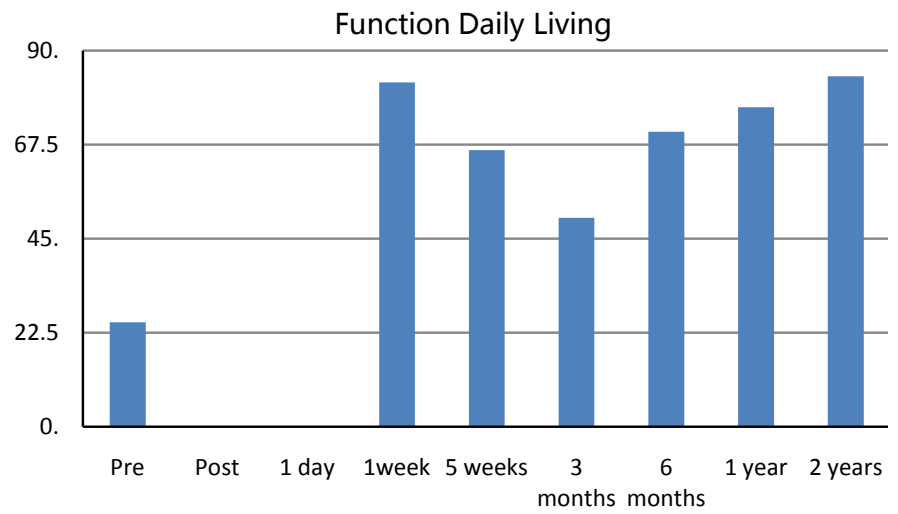


Figure 4. KOOSADL score 0 - 100. 100 perfect score.

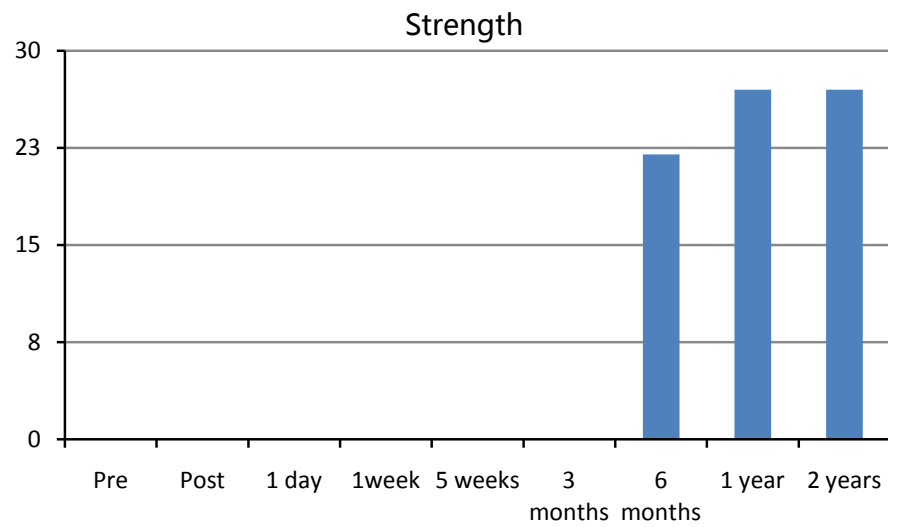


Figure 5. Quadriceps strength in lbs./in².

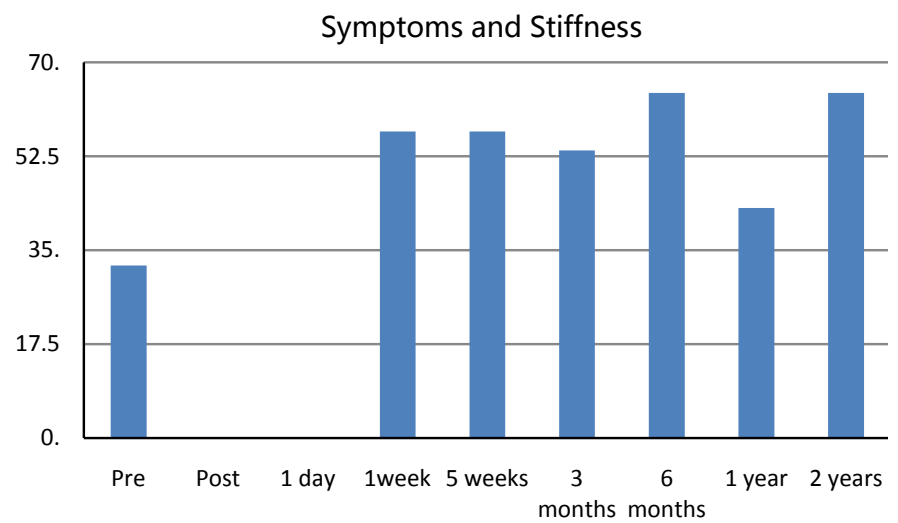


Figure 6. KOOS symptoms and stiffness 0 - 100. 100 perfect score.

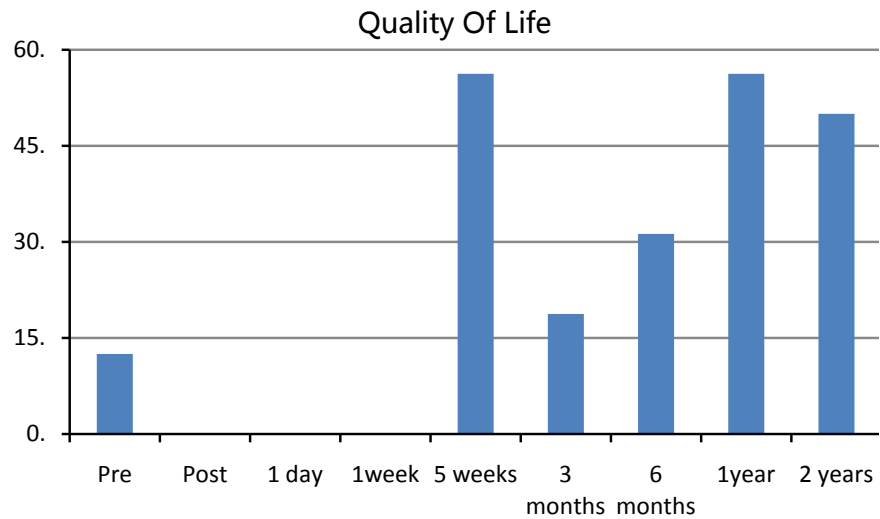


Figure 7. KOOS quality of life score 0 - 100. 100 perfect score.

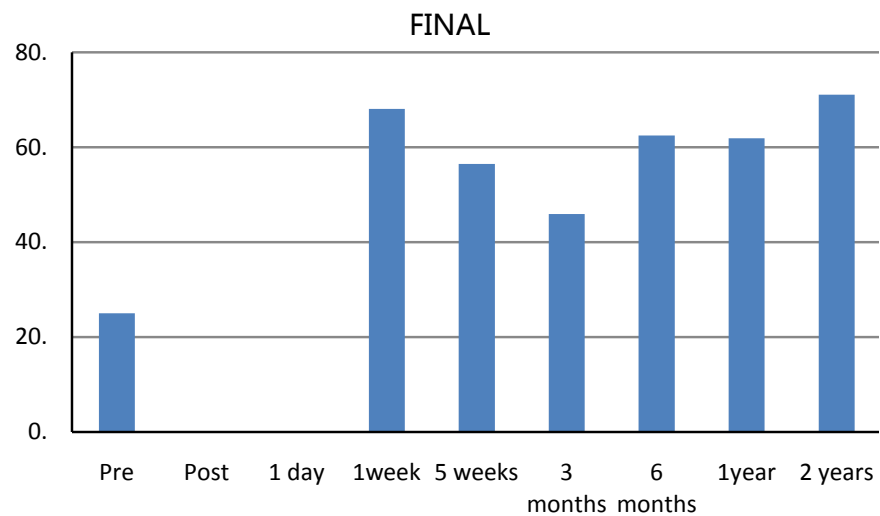


Figure 8. KOOS all scores combined score 0 - 100. 100 perfect score.

patients.

In most cases where patients have failed the current standards of non-surgical care, the only option is joint replacement, particular for elderly patients [1].

In this panorama regenerative medicine may give a new option for those who are not candidates for surgery, do not want surgery or are unable to have surgery due to concomitant medical conditions. Here the biological deployment of fat graft may potentially prove a viable option to reduce pain, restore function, improve quality of life and show promise in halting the degenerative.

Lipogems® system has been developed to improve the classical fat graft lipofiling technique [15] with the aim of providing transplantable clusters of lipoaspirate with reduced size to improve engraftment. The system is a disposable kit for the aspiration, processing and reinjection of autologous adipose tissue in both human and veterinary medicine [18] [23]. Its core is a disposable and closed device filled with saline solution that progressively reduces the size of the clusters

of adipose tissue by means of mild mechanical forces and eliminates oil and blood residues responsible for the inflammation processes. The technique is non-traumatic and intra-operatively provides micro-fragmented fat in a short time (15 - 20 minutes), without expansion and/or enzymatic treatment. The vasculo stromal niches of Lipogems® survive in the site of the injection and improve tissue health benefits [23]. Micro-fragmented clusters contain small-sized, intact adipocytes that may play an important role in cell paracrine action.

The positive clinical outcome, in a joint that would have been considered resilient to improvement, with the potential repair and regeneration of the cartilage is very promising. Adipose tissue has been positively highlighted in different studies detailing a cascade of events including signaling, trophic, immunomodulatory, mitogenic, anti-microbial, anti-scarring, and anti-apoptotic properties that contribute to potential regenerative mechanisms.

While more studies are required to validate the effectiveness of this approach for the treatment of knee pain, this data is very encouraging.

Theories as to mechanism of action may include the micro-fragmented adipose tissue providing volume, support, cushioning, filling of soft tissue defects or potential healing and regenerative capabilities. Additional mechanisms may include direct differentiation and chondrogenesis, regenerative signaling by activated perivascular cells tissue repair, signaling of trophic and paracrine mediators [19], activation of opioid receptors [24], pain reduction, down-regulation of destructive cytokines in the microenvironment, reduction of the arthrogenic muscle inhibition [25], exosome initiated cascades or a combination of all of these.

The improvement in measured outcomes for pain, KOOS, MRI imaging, quadriceps strength and range of motion showing sustained gains up to 2.5 years support these theories.

The results in this case report supported with other case studies about the regenerative potential of micro-fragmented adipose tissue in the treatment of knee pain and joint degeneration are encouraging.

Fat tissue transfer with Lipogems harvesting device appears to provide a viable option for the painful knee after the initial diagnosis including advanced osteoarthritis in those patients who fail conventional treatments, and do not want or are not candidates for surgery.

8. Conclusion

While this is a Level 5 single case study, on a subject with severe joint pathology and instability, the injections of autologous, micro-fragmented, and minimally manipulated adipose tissue resulted in significant improvement in pain, function and quality of life. No adverse events were reported. Several studies are ongoing needed to confirm this result.

References

- [1] Heidari, B. (2011) Knee Osteoarthritis Prevalence, Risk Factors, Pathogenesis and

Features: Part I. *Caspian Journal of Internal Medicine*, **2**, 205-212.

- [2] Hayami, T. (2008) Osteoarthritis of the Knee Joint as a Cause of Musculoskeletal Ambulation Disability Symptom Complex (MADS). *Clinical Calcium*, **18**, 1574-1580.
- [3] Hochberg, M.C., Altman, R.D., Brandt, K.D., Clark, B.M., Dieppe, P.A., Griffin, M.R., Moskowitz, R.W. and Schnitzer, T.J. (1995) Guidelines for the Medical Management of Osteoarthritis. *Arthritis & Rheumatology*, **38**, 1535-1540.
<https://doi.org/10.1002/art.1780381103>
- [4] Zhang, W., Moskowitz, R., Nuki, G., Abramson, S., Altman, R., Arden, N., Bierma-Zeinstra, S., Brandt, K.D., Croft, P., Doherty, M., Dougados, M., Hochberg, M., Hunter, D.J., Kwoh, K., Lohmander, L.S. and Tugwell, P. (2008) Recommendations for the Management of Hip and Knee Osteoarthritis, Part II: OARSI Evidence-Based, Expert Consensus Guidelines. *Osteoarthritis Cartilage*, **16**, 137-162.
<https://doi.org/10.1016/j.joca.2007.12.013>
- [5] Niethard, F.U., Gold, M.S., Solomon, G.S., Liu, J.-M., Unkauf, M., Albrecht, H.H. and Elvik, F. (2005) Efficacy of Topical Diclofenac Diethylamine Gel in Osteoarthritis of the Knee. *The Journal of Rheumatology*, **32**, 2384-2392.
- [6] Østergaard, M. and Halberg, P. (1998) Intra-Articular Corticosteroids in Arthritic Disease: A Guide to Treatment. *BioDrugs*, **9**, 95-103.
<https://doi.org/10.2165/00063030-199809020-00002>
- [7] Canaider, S., Maioli, M., Facchin, F., *et al.* (2014) Human Stem Cell Exposure to Developmental Stage Zebrafish Extracts: A Novel Strategy for Turning Stemness and Senescence Patterning. *CellR4*, **2**, 1226.
- [8] Huang, J.I., Beanes, S.R., Zhu, M., Lorenz, H.P., Hedrick, M.H. and Benhaim, P. (2002) Rat Extramedullary Adipose Tissue as a Source of Osteochondrogenic Progenitor Cells. *Plastic and Reconstructive Surgery*, **109**, 1033-1041.
<https://doi.org/10.1097/00006534-200203000-00037>
- [9] Caplan, A.I. (2007) Adult Mesenchymal Stem Cells for Tissue Engineering versus Regenerative Medicine. *Journal of Cellular Physiology*, **213**, 341-347.
<https://doi.org/10.1002/jcp.21200>
- [10] Caplan, A.I. and Dennis, J.E. (2006) Mesenchymal Stem Cells as Trophic Mediators. *Journal of Cellular Biochemistry*, **98**, 1076-1084. <https://doi.org/10.1002/jcb.20886>
- [11] Bianchi, F., Maioli, M., Leonardi, E., Olivi, E., Pasquinelli, G., Valente, S., *et al.* (2013) A New Non Enzymatic Method and Device to Obtain a Fat Tissue Derivative Highly Enriched in Pericyte-Like Elements by Mild Mechanical Forces from Human Lipoaspirates. *Cell Transplantation*, **22**, 2063-2077.
<https://doi.org/10.3727/096368912X657855>
- [12] Von Heinburg, D., Hemmrich, K., Haydarlioglu, S., *et al.* (2004) Comparison of Viable Cell Yield from Excised Versus Aspirated Adipose Tissue. *Cells Tissues Organs*, **178**, 87. <https://doi.org/10.1159/000081719>
- [13] Strem, B.M., Hicok, K.C., Zhu, M., *et al.* (2005) Multipotential Differentiation of Adipose Tissue-Derived Stem Cells. *The Keio Journal of Medicine*, **54**, 132.
<https://doi.org/10.2302/kjm.54.132>
- [14] Tremolada, C., Colombo, V. and Ventura, C. (2016) Adipose Tissue and Mesenchymal Stem Cells: State of the Art and Lipogems Technology Development. *Current Stem Cell Reports*, **2**, 304-312. <https://doi.org/10.1007/s40778-016-0053-5>
- [15] Coleman, S.R. (2006) Structural Fat Grafting: More Than a Permanent Filler. *Plastic and Reconstructive Surgery*, **118**, 108-120.
<https://doi.org/10.1097/01.prs.0000234610.81672.e7>

- [16] Coleman, S.R. (1998) Structural Fat Grafting. *Journal of Cutaneous and Aesthetic Surgery*, **18**, 386-388. [https://doi.org/10.1016/S1090-820X\(98\)70098-6](https://doi.org/10.1016/S1090-820X(98)70098-6)
- [17] Gimble, J.M., Bunnell, B.A., Chiu, E.S. and Guilak, F. (2011) Concise Review: Adipose Derived Stromal Vascular Fraction Cells and Stem Cells: Let's Not Get Lost in Translation. *Stem Cells*, **29**, 749-754. <https://doi.org/10.1002/stem.629>
- [18] Components, P. (2012) Understanding Adipose-Derived Stromal Vascular Fraction (AD-SVF) Cell Biology and Use on the Basis of Cellular, Chemical, Structural and Paracrine Components: a Concise review. *Prolotherapy*, **4**, e855-e869.
- [19] Mestak, O., Sukop, A., Hsueh, Y.S., *et al.* (2014) Centrifugation versus Pure Graft for Fat Grafting to the Breast after Breast-Conserving Therapy. *World Journal of Surgical Oncology*, **12**, 178. <https://doi.org/10.1186/1477-7819-12-178>
- [20] Alexander, R.W. (2011) Autologous Fat Grafts as Mesenchymal Stromal Stem Cell Source for Use in Prolotherapy: A Simple Technique to Acquire Lipoaspirants. *Prolotherapy*, **3**, 680-688.
- [21] Garcia-Contreras, M., Messaggio, F., Jimenez, O. and Mendez, A. (2014) Differences in Exosome Content of Human Adipose Tissue Processed by Non-Enzymatic and Enzymatic Method. *CellR4*, **3**, e1423.
- [22] Rani, S., Ryan, A.E., Griffin, M.D. and Ritter, T. (2015) Mesenchymal Stem Cell-Derived Extracellular Vesicles: Toward Cell-Free Therapeutic Applications. *Molecular Therapy*, **23**, 812-823. <https://doi.org/10.1038/mt.2015.44>
- [23] Carelli, S., Messaggio, F., Canazza, A., *et al.* (2015) Characteristics and Properties of Mesenchymal Stem Cells Derived from Microfragmented Adipose Tissue. *Cell Transplant*, **24**, 1233-1252. <https://doi.org/10.3727/096368914X681603>
- [24] Guo, W., Wang, H., Zou, S., Gu, M., Watanabe, M., Wei, F., Dubner, R., Huang, J.T. and Ren, K. (2011) Bone Marrow Stromal Cells Produce Long Term Pain Relief in Rat Models of Persistent Pain. *Stem Cells*, **29**, 1294-1303. <https://doi.org/10.1002/stem.667>
- [25] Keller, K. and Engelhardt, M. (2014) Arthrogenic Muscle Inhibition after Trauma—Is There an Age Dependency of the Intensity of Arthrogenic Muscle Inhibition? *Sportverletz Sportschaden*, **28**, 199-203.



Submit or recommend next manuscript to SCIRP and we will provide best service for you:

Accepting pre-submission inquiries through Email, Facebook, LinkedIn, Twitter, etc.
A wide selection of journals (inclusive of 9 subjects, more than 200 journals)
Providing 24-hour high-quality service
User-friendly online submission system
Fair and swift peer-review system
Efficient typesetting and proofreading procedure
Display of the result of downloads and visits, as well as the number of cited articles
Maximum dissemination of your research work

Submit your manuscript at: <http://papersubmission.scirp.org/>

Or contact ojrm@scirp.org